

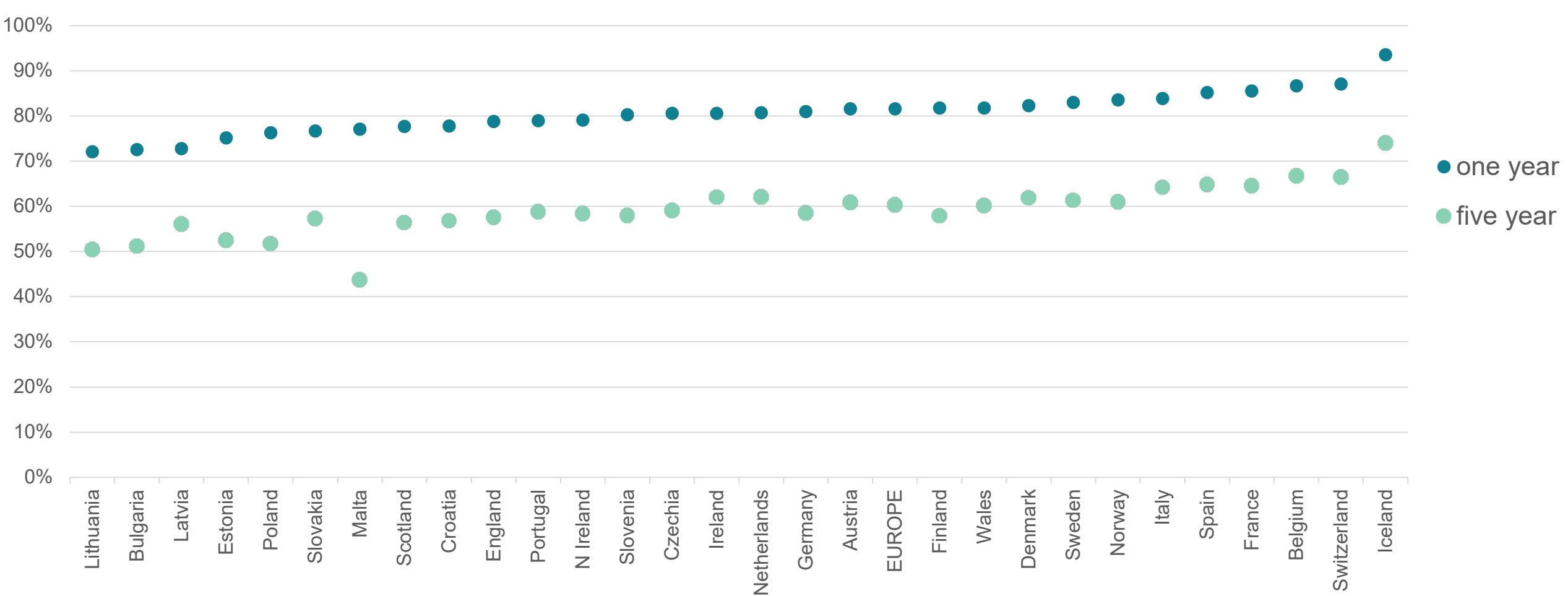


Sarcoma

Coding issues

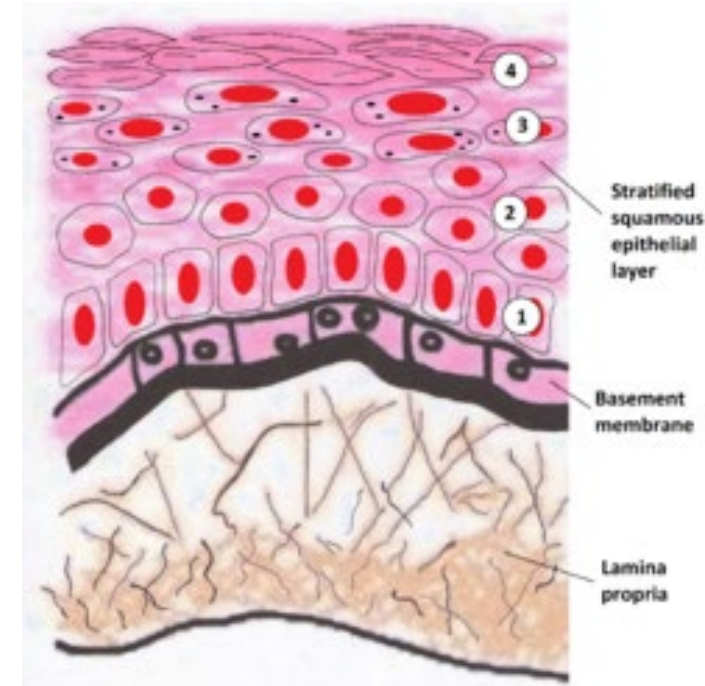
Otto Visser
May 2021

Relative survival of soft tissue cancer (2000-2007)



What is a sarcoma?

- A sarcoma is a malignant tumour that arises in tissues that were formed from the mesoderm, the 'middle' germ layer of the embryo
- In those tissues no 'basement membrane' is present
- Therefore, the behaviour of the tumour (the potency to metastasize) cannot be determined on the basis of invasion of the basement membrane (as in all epithelial cancers), but has to be determined on other factors

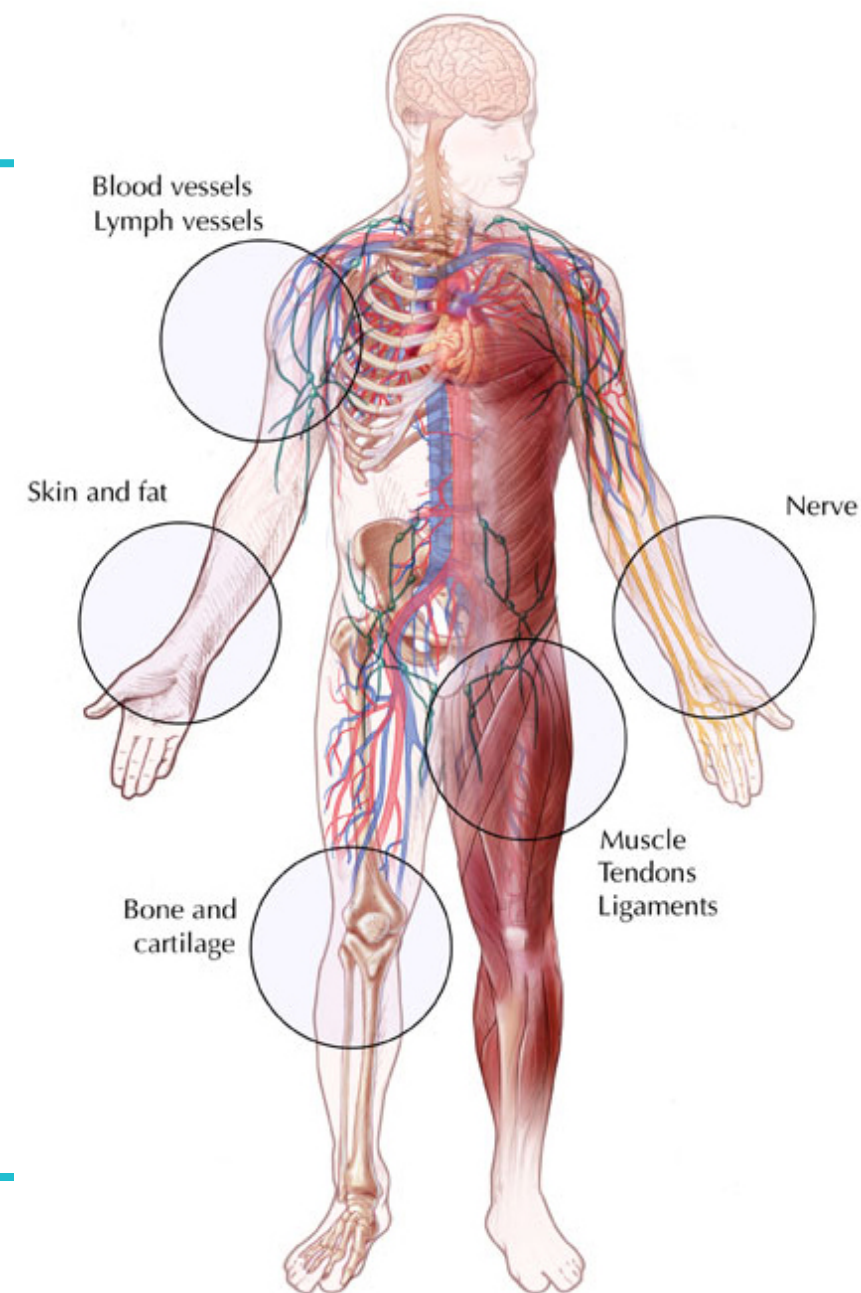




Topography

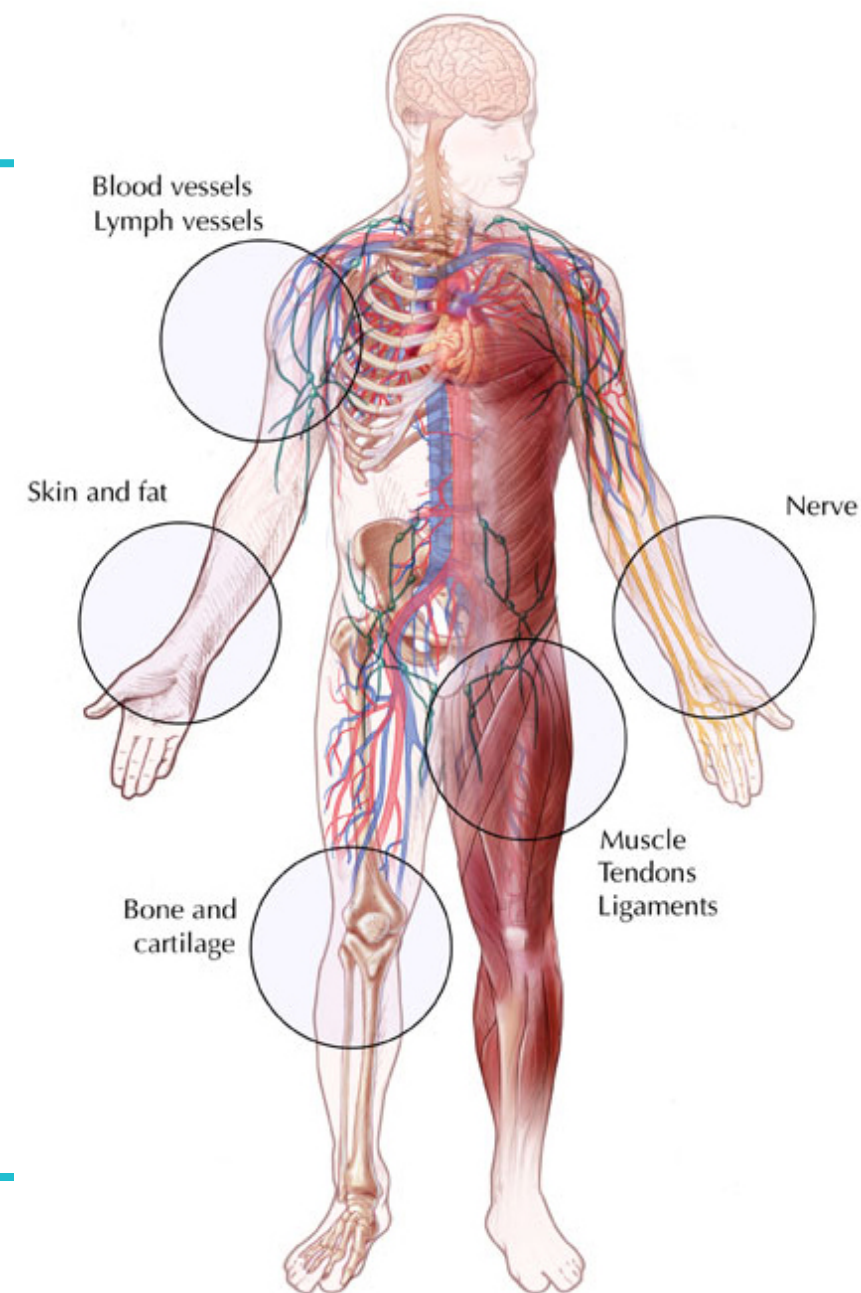
Sarcoma: main sites

- Bone and cartilage
- 'Soft tissues'
 - Skin and subcutaneous tissues
 - Blood and lymph vessels
 - Muscles, tendons, ligaments
 - Nerves
- Organs
 - Stomach, uterus, etc.



Sarcoma: main sites

- Bone and cartilage → C40, C41
- 'Soft tissues'
 - Soft tissues → C49
 - Peripheral nerves & ANS → C47
 - Retroperitoneum → C48.0
 - Mediastinum → C38.1-3
- Organs
 - Gastrointestinal tract, lung, uterus, etc. → code to the specific organ, e.g. C16-C25, C34, C54, etc.



Topography of sarcoma: some issues

- Sarcoma of the skin: C44 (cutaneous leiomyosarcoma, Kaposi sarcoma, dermatofibrosarcoma, angiosarcoma, pleomorphic sarcoma [MFH] of the skin)
- Subcutaneous sarcoma: C49
- Malignant peripheral nervous system tumour: C47 (except when organ-derived)
- Paratesticular sarcoma: C63.7



Morphology

Introduction

- For most (solid) cancers, the primary site of the most important factor for the prognosis and the choice of treatment
- For other cancers, especially haematological malignancies, but also for an increasing number of solid cancers, the morphological classification is the most important factor
- This is also true for sarcoma

Sarcoma: main histological types

- Bone → osteosarcoma; cartilage → chondrosarcoma
- 'Soft tissues'
 - Skin and subcutaneous tissues (fat → liposarcoma; connective tissue → fibrosarcoma)
 - Blood and lymph vessels → (lymph)angiosarcoma
 - Muscles → rhabdomyosarcoma (striated muscle) or leiomyosarcoma (smooth muscle); tendons → synoviosarcoma
 - Nerves → malignant peripheral nerve sheath tumour (MPNST)
- In organs, almost all types can occur as in most organs all kinds of soft tissues are present (fat, connective tissue, smooth muscle, blood vessel)

Sarcoma: other/rare types

- Stromal cells → gastrointestinal stromal tumour (GIST), stromal sarcoma
- Osteoclasts → osteoclastoma (giant cell tumour of bone); *rarely malignant*
- Peripheral neuroectoderm → peripheral neuroectodermal tumour (PNET)
- Small blue round cell tumours, such as Ewing's sarcoma [t(11;22)] and desmoplastic small round cell tumour
- Kaposi's sarcoma (a blood vessel tumour of the skin; often with multiple lesions)
- Remnants of the chorda → chordoma (considered as a bone tumour)

Sarcoma: other/rare types

- Mesothelium → mesothelioma
- Meninges → meningioma

Sarcoma: a-specific types

- Spindle cell sarcoma
- Pleomorphic cell sarcoma
- Small cell sarcoma
- Giant cell sarcoma (except of bone)
- Epithelioid sarcoma
- Undifferentiated sarcoma
- Malignant fibrous histiocytoma

If there is a specific diagnosis and an a-specific diagnosis, the specific diagnosis has preference.

Sarcoma: a-specific versus specific

Epithelioid angiosarcoma → not in ICD-O

- Epithelioid sarcoma → 8804
- Angiosarcoma → 9120
- Epithelioid angiosarcoma → 9120

Pleomorphic leiomyosarcoma → not in ICD-O

- Pleomorphic sarcoma → 8802
- Leiomyosarcoma → 8890
- Pleomorphic leiomyosarcoma → 8890

New morphology codes in 2nd revision of ICD-O-3

Code	Term
8714/3	Malignant PEComa (perivascular epithelioid tumour)
8842/3*	Ossifying fibromyxoid tumor, malignant
8983/3*	Malignant adenomyoepithelioma
9045/3	Biphenotypic sinonasal sarcoma
9137/3	Intimal sarcoma
9222/1	Atypical cartilaginous tumour
9302/3*	Ghost cell odontogenic carcinoma
9341/3*	Clear cell odontogenic carcinoma

* A code for the benign tumour was already available

Change of behaviour code in 2nd revision of ICD-O-3

Term	Old code	New code
Dermatofibrosarcoma (protuberans)	8832/3	8832/ 1
Pigmented dermatofibrosarcoma (Bednar tumour)	8833/3	8833/ 1
Dermatofibrosarcoma, sarcomatous	8832/3	8832/ 3
Epithelioid haemangioendothelioma, NOS	9133/1	9133/ 3
Chondrosarcoma, grade 1	9220/31	9222/ 1

Sarcoma: grade

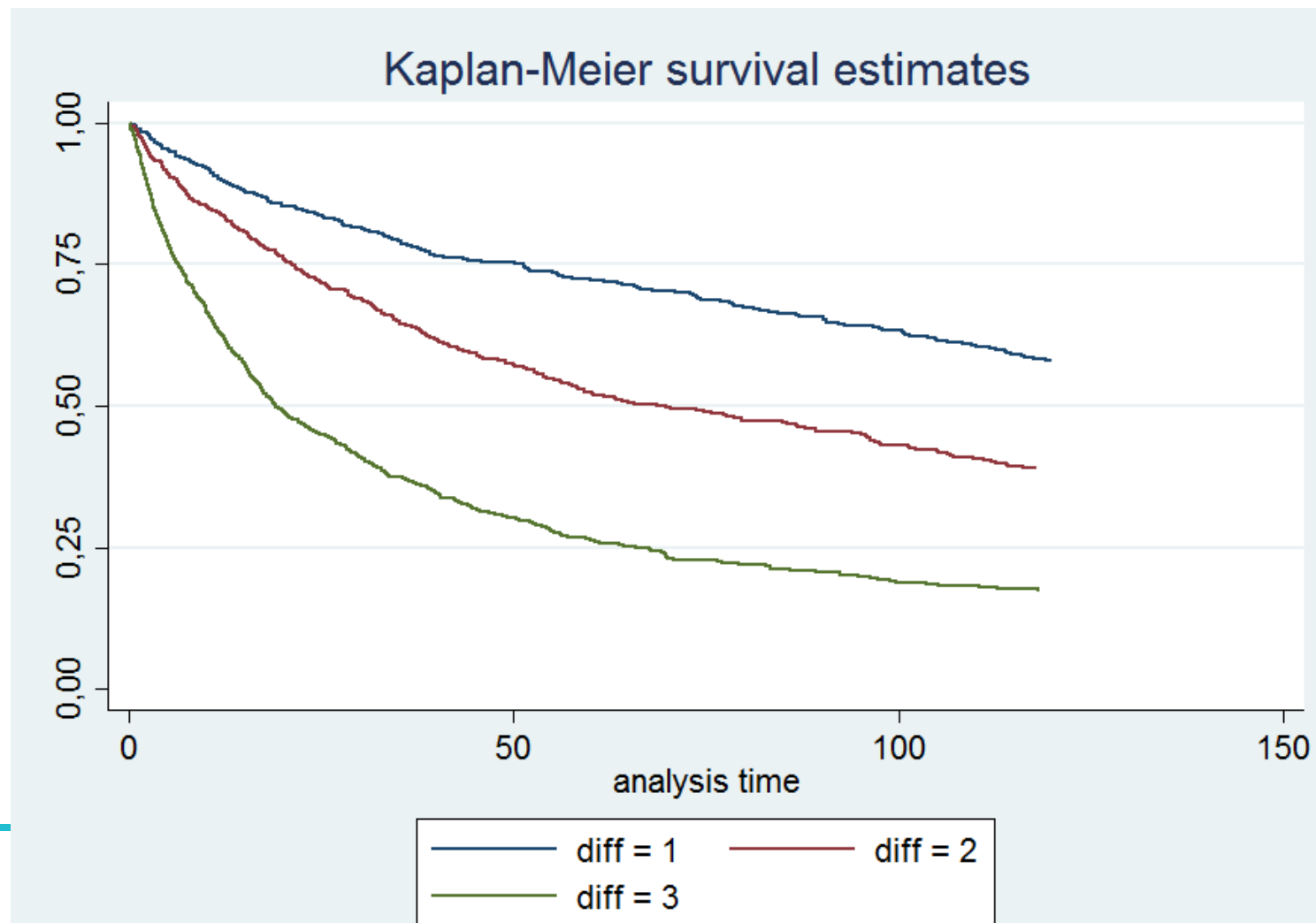
- For most sarcomas a grading system is used by the pathologist to indicate the potency for recurrence and/or distant metastasis (grade 1: low; grade 2: intermediate; grade 3: high)
- Most relevant for
 - liposarcoma, fibrosarcoma,
 - leiomyosarcoma, chondrosarcoma,
- Always considered high grade
 - rhabdomyosarcoma, osteosarcoma, angiosarcoma,
 - PNET, Ewing sarcoma

Survival of leiomyosarcoma according to grade

Grade 1: 10-year survival
~60%

Grade 2: 10-year survival
~40%

Grade 3: 10-year survival
~20%



Grade 1 liposarcoma and chondrosarcoma

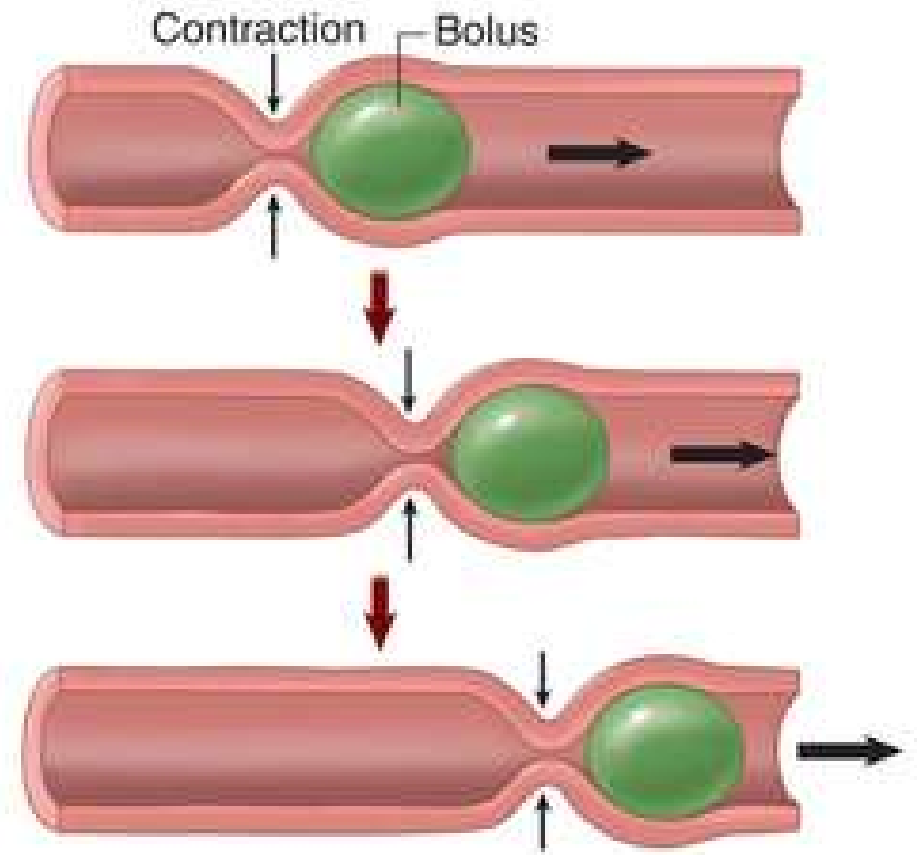
According to the latest version of the WHO classification of sarcomas grade 1 (well differentiated) liposarcoma (8850/31 or 8851/31) and grade 1 chondrosarcoma (9220/31) are no longer considered malignant and should be classified with behaviour code 1 (8850/11 and 9222/11, respectively).

For international comparison the behaviour code is of less relevance as long as the correct grade is coded.

Within grade I tumours, dedifferentiation may occur and you should code it as a dedifferentiated (= high grade) sarcoma

GIST

- GIST is a tumour of the Cajal cells in the wall of the stomach and the bowel
- the Cajal cells serve as a pacemaker for the contraction of the stomach and bowel (peristaltic movement)
- those cells are not present in other organs or soft tissues



GIST

The potency for recurrence or metastases of GIST is dependent of

- size of the tumour
- number of mitoses

According to ICD-O-3.2 all GIST have to be registered as malignant (behaviour code /3)

It is recommended to register the tumour size and the number of mitoses

Combination of topography and morphology

Typical bone tumours can also occur in organs or soft tissues ('extraskeletal osteosarcoma', etc.): code to the site of origin and not on bone.

Example:

osteosarcoma primary to the duodenum → topography C17.0

Typical soft tissue tumours can also occur in organs or bone

Example:

Fibrosarcoma primary to the humerus → topography C40.0

Combination of topography and morphology

Chordoma is considered a bone tumour

Examples:

- *pre-pontine chordoma/ near the cerebellum / sella region → topography C41.0*
- *sacral chordoma → topography C41.4*

Combination of topography and morphology

PNET can occur in the CNS and in bone/soft tissue but has different morphology codes

- PNET in CNS: M9473 (central PNET')
- PNET in bone/soft tissue: M9364 (peripheral PNET')

Rhabdoid tumours can occur in the CNS and in bone/soft tissue but have different morphology codes

- Rhabdoid tumour in CNS: M9508 ('atypical teratoid/rhabdoid tumour')
- Rhabdoid tumour outside CNS: M8963 ('malignant rhabdoid tumour'/'rhabdoid sarcoma')

GIST

Although GISTs sometimes appear not to have its origin in the stomach or the bowel, the origin is probably always in the bowel or the stomach

- GIST in the left upper abdomen (C76.2) → stomach (C16)
- GIST in the lesser omentum (C48.1) → stomach (C16)
- GIST in the greater omentum (C48.1) → stomach (C16)
- GIST in the lower abdomen (C76.2) → bowel, NOS (26.0)
- GIST in the peritoneum of the ileum (C48.2) → ileum (C17.2)
- GIST in the rectovaginal/rectovesical septum (C76.3) → rectum (C20.9)

How to code a *black & white cow*?

1. Red cow
2. Cow, NOS
3. Purple cow
4. *Black & white striped zebra*





EXERCISES



www.enchr.eu



European Network
of Cancer Registries



European
Commission